

**OFFICE OF THE MEDICAL EXAMINER
DISTRICT NINE
2350 E. Michigan Street
Orlando, Florida 32806-4939**

REPORT OF AUTOPSY

DECEDENT: CHRISTINA GRIMMIE **CASE NUMBER:** ME 2016-000903

MANNER OF DEATH: Homicide **IDENTIFIED BY:** Marcus Grimmie

AGE: 22 years
RACE: White

SEX: Female
DATE OF DEATH: June 10, 2016

DATE/TIME OF AUTOPSY: June 11, 2016 @ 8:30 a.m.

 , MD 7/22/16

PERFORMED BY: Joshua D. Stephany, MD, Chief Medical Examiner

CAUSE OF DEATH: Gunshot wounds of head and chest

AUTOPSY FINDINGS

- I. Penetrating, close-range gunshot wound of the head:
 - A. Entrance gunshot wound of the right temporal scalp
 - B. Stippling is present
 - C. Soot and muzzle imprint are absent
 - D. Hemorrhage of the right temporalis muscle
 - E. Comminuted fractures of the right temporal and occipital bones
 - F. Cortical contusions and lacerations of the base of the right temporal lobe
 - G. Deformed copper-jacketed lead projectile recovered from the posterior scalp adjacent to the outer table of the right occipital bone
 - H. The direction of the path of the wound is front to back, right to left, and downward

GRIMMIE, CHRISTINA
ME 2016-000903
PAGE 2

- II. Penetrating gunshot wound of the chest:
- A. Entrance wound on the right chest
 - B. Stippling, soot, and muzzle imprint are absent
 - C. Fractures of the anterior aspect of the 6th right rib
 - D. Perforation of the right lower lung lobe
 - E. Laceration of the pericardial sac
 - F. Lacerations of the right atrium of the heart
 - G. Lacerations of the right 9th intercostal musculature
 - H. Lacerations of the musculature of the right back
 - I. Partially deformed copper-jacketed lead projectile recovered from the subcutaneous soft tissue of the right back
 - J. The direction of the path of the wound is front to back, and slightly left to right
 - K. Hemopericardium (20 milliliters)
 - L. Bilateral hemothoraces (right 1200 milliliters, left 100 milliliters)
- III. Penetrating gunshot wound of the chest:
- A. Entrance wound on the superior left shoulder
 - B. Stippling, soot, and muzzle imprint are absent
 - C. Fractures of the posterior aspects of the 3rd and 4th left ribs
 - D. Perforation of the left lower lung lobe
 - E. Partially deformed copper-jacketed lead projectile recovered from the left lower lung lobe
 - F. Left hemothorax (100 milliliters)
 - G. The direction of the path of the wound is downward

TOXICOLOGY ANALYSIS: See laboratory report.

CONCLUSION: In consideration of the circumstances surrounding the death, and after examination of the body, toxicology analysis, and review of the available medical records, it is my opinion that the death of Christina Grimmie, a 22-year-old white female witnessed to have been shot by another and subsequently transported to the hospital, is the result of a gunshot wounds of the head and chest.

The manner of death is homicide.

GRIMMIE, CHRISTINA
ME 2016-000903
PAGE 3

The autopsy of the body of Christina Grimmie is performed pursuant to Florida Statute 406.11 by Joshua D. Stephany, MD, Chief Medical Examiner, District Nine at the Orange County Medical Examiner facility, Orlando, Florida on June 11, 2016 @ 8:30 a.m.

IDENTIFICATION: The body of Christina Grimmie is identified by Marcus Grimmie, her brother. The identification is made to emergency medical personnel on June 10, 2016 @ 10:30 p.m., at the scene.

CLOTHING AND VALUABLES: At the time of examination, the decedent is dressed in a cut black sleeveless shirt, cut black bra, cut underwear, cut black shorts and a cut black skirt. A black necklace is around the neck. A bracelet is around the wrist.

GENERAL STATEMENT: The body is that of a well-developed, well-nourished, 63 inch, 114 pound, adult white female, consistent with the reported age of 22 years. Brown paper bags are on placed on the hands and feet at the hospital. The seals remain intact at the time of examination.

EXTERNAL EXAMINATION

The scalp is covered by up to 26 cm long, black hair that is partially dyed blue. The irides are brown and the sclerae are white. The conjunctivae have no petechiae. The external nose has no trauma and the nasal septum is intact. The frenula are intact and the oral mucosa has no trauma. The teeth are natural and in adequate condition. The neck is unremarkable.

The torso has congenital deformities, scars, or tattoos. The pubic region has been shaven antemortem. The breasts are symmetric, equal and have no palpable masses. The external genitalia are those of an adult female. The anus is normal.

The extremities have no injuries, congenital deformities, or tattoos. A tattoo in black ink of "All Is Vanity" is on the ventral right forearm. A tattoo in black in of "L" is on the ventral right wrist. A tattoo in black ink of "2P" is on the ventral left forearm.

GRIMMIE, CHRISTINA
ME 2016-000903
PAGE 4

EVIDENCE OF MEDICAL INTERVENTION

Electrocardiogram pads are on the right chest, left chest, right thigh, and left thigh. An intraosseous catheter is in the right shoulder. External defibrillator pads are on the right chest and left abdomen. An intravenous catheter is in the left antecubital fossa. A chest tube attempt is in the right pleural cavity through the 7th intercostal musculature. A chest tube is in the left pleural cavity through the 5th intercostal musculature. A hospital identification band is around the right ankle.

EVIDENCE OF INJURY

Penetrating close-contact gunshot wound of the head:

A 1 x 1 cm round entrance gunshot wound with a 0.3 cm abrasion at the 3 o'clock position is on the right temporal scalp, 3 inches below the top of the head and 6 inches right of the anterior midline. A triangular stippling pattern is adjacent to the gunshot wound spreading 6 cm from the edge of the entrance wound at the 2 o'clock position, 4 cm from the edge of the entrance wound at the 3 o'clock position, and 4 cm from the edge of the entrance wound at the 4 o'clock position. Soot and muzzle print are absent.

The wound path is hemorrhagic and traverses the skin of the right temporal scalp, right temporalis muscle, right temporal bone, right temporal lobe, and right occipital bone.

A partially-deformed, copper-jacketed lead projectile is recovered from the posterior scalp, adjacent to the outer table of the right occipital bone.

Associated with the path of the wound are hemorrhage and lacerations of the right temporalis muscle, diffuse subgaleal hemorrhage over the outer table of the right skull, linear and comminuted fractures of the right temporal bones and right occipital bone, and lacerations and contusions of the base of the right temporal lobe.

The direction of the path of the wound is front to back, right to left, and downward.

GRIMMIE, CHRISTINA
ME 2016-000903
PAGE 5

Penetrating gunshot wound of the chest:

A 1 x 1 cm entrance gunshot wound with a 0.1 cm wide pink-red abrasion rim is on the right chest, 16½ inches below the top of the head, 1¼ inches right of the anterior midline. Stippling, soot, and muzzle imprint are absent. A faint purple contusion is adjacent to the entrance wound at the 3 o'clock position.

The wound path is hemorrhagic and traverses the musculature of the right chest, anterior aspect of the 6th right rib, right lower lung lobe, pericardial sac, right atrium of the heart, posterior aspect of the right 9th intercostal muscle, and musculature of the right back.

A deformed copper-jacketed lead projectile is recovered from the subcutaneous soft tissue of the right back, 16½ inches below the top of the head, and 2 inches right of the posterior midline.

Associated with the path of the wound are lacerations and hemorrhage of the musculature of the right chest, fractures of the anterior aspect of the 6th right rib, perforation of the right lower lung lobe, lacerations of the right atrium of the heart, lacerations of the right posterior 9th intercostal muscle, lacerations of the musculature of the right back, approximately 20 milliliters of blood in the pericardial sac, approximately 1200 milliliters of blood in the right pleural cavity and approximately 100 milliliters of blood in the left pleural cavity.

The direction of the path of the wound is front to back, slightly left to right, with no up or down trajectory.

Penetrating gunshot wound of the chest:

A 1 x 1 cm round entrance gunshot wound with an up to 0.4 cm wide circumferential pink abrasion rim is on the superior left shoulder, 9½ inches below the top of the head, and 4 inches of the left of the anterior midline. Stippling, soot, and muzzle imprint are absent.

The wound path is hemorrhagic and traverses the musculature of the left upper chest, posterior aspects of the 3rd and 4th left ribs, and left lower lung lobe.

A deformed copper-jacketed lead projectile is recovered from the left lower lung lobe.

GRIMMIE, CHRISTINA
ME 2016-000903
PAGE 6

Associated with the path of the wound are lacerations and hemorrhage of the musculature of the left chest, perforation of the left lower lung lobe, fractures of the posterior aspects of the 3rd and 4th left ribs, and approximately 100 milliliters in the left pleural cavity.

The direction of the path of the wound is downward with no significant front to back or left to right trajectory.

INTERNAL EXAMINATION

The pleural cavities and pericardial sac have no adhesions. The peritoneal cavity has no excess fluid or adhesions.

CARDIOVASCULAR SYSTEM: The heart is 240 grams and has a normal distribution of epicardial fat. The coronary arteries are patent. The right coronary artery is dominant. The myocardium is dark red, firm, and has no scars. The left ventricle is 1 cm thick and 2 cm in internal diameter. The right ventricle is 0.3 cm thick and 3 cm in internal diameter. The tricuspid, pulmonary, mitral, and aortic valves are thin, pliable, and have no vegetations. The aorta is elastic and has a smooth intimal lining.

RESPIRATORY SYSTEM: The right lung is 170 grams and the left lung is 340 grams. The pleural surfaces are tan-pink, smooth, and glistening. The lung parenchyma is tan-pink to dark red, soft, and focally hemorrhagic. The larynx and trachea are patent and lined by tan, intact mucosa. The pulmonary vessels are patent.

HEPATOBIILIARY SYSTEM: The liver is 870 grams and has a smooth, tan-brown, and intact capsule. The parenchyma is tan-brown and firm. The gallbladder contains approximately 5 milliliters of dark green, viscous bile and no choleliths. The gallbladder mucosa is dark green and velvety.

RETICULOENDOTHELIAL SYSTEM: The spleen is 120 grams and has a purple, finely wrinkled, and intact capsule. The parenchyma is dark red and soft. The cervical, mediastinal, and abdominal lymph nodes are not enlarged.

GRIMMIE, CHRISTINA
ME 2016-000903
PAGE 7

GASTROINTESTINAL TRACT: The tongue has no bite marks or hemorrhage. The esophagus is lined by tan, intact mucosa. The serosa of the stomach is tan-gray and glistening. The stomach contains approximately 5 milliliters of green fluid and partially digested amorphous white chewing gum. The gastric mucosa is tan, has unremarkable rugal folds, and is intact. The external surfaces of the intestines are tan-gray and have no palpable masses. The vermiform appendix is tan-gray and glistening.

GENITOURINARY SYSTEM: The right kidney is 100 grams and the left kidney is 100 grams. The capsules are adhered to tan, smooth cortical surfaces. The parenchyma is tan-red and has well-defined corticomedullary demarcation. The ureters have a normal course and caliber. The urinary bladder contains approximately 20 milliliters of yellow urine and has a tan, trabeculated, and intact mucosa.

The uterus, fallopian tubes, and ovaries, are unremarkable.

ENDOCRINE SYSTEM: The adrenal glands have well-demarcated, thin, golden yellow cortices, and gray medullae. The pancreas is tan and lobular. The thyroid gland is dark red, uniform, and not enlarged.

NECK: The anterior muscles and surrounding soft tissue of the neck have no hemorrhage. The hyoid bone and thyroid cartilage are intact.

HEAD: Injuries to the head are previously described. The brain is 1190 grams. Epidural hemorrhage is absent. The leptomeninges are thin, transparent and have no exudate. The vessels at the base of the brain are normally formed and are patent. The uninjured portions of the cerebral hemispheres are symmetric, the gyri are flattened and the sulci are effaced. Coronal sections of the cerebrum and transverse sections of the cerebellum and brainstem reveal no neoplasm, or necrosis.

JDS/jw

Patient: **GRIMMIE, CHRISTINA**
 Client Patient ID: **9-16-903**
 Physician: **STEPHANY, JOSHUA**

 Age: **22** Sex: **F**
 Account#: **VX82877**
 Client: **DIST 9 MEDICAL EXAMINER**
TOXICOLOGY

Specimen Collected :06/11/2016

Lab Order No: 661300932

Reg Date: 06/13/16

Test Name	Result	Units	Cutoff/Reporting Limits
-----------	--------	-------	-------------------------

VOLATILE PANEL - VOLP

SPECIMEN TYPE

PERIPHERAL BLOOD

ETHANOL	NONE DETECTED	g/dL	0.010
ACETONE	NONE DETECTED	mg/dL	7.5
METHANOL	NONE DETECTED	mg/dL	15.0
ISOPROPANOL	NONE DETECTED	mg/dL	15.0

Analysis by Gas Chromatography (GC) Headspace Injection

BLOOD DRUG SCREEN - BDSME

SPECIMEN TYPE

RIGHT CHEST BLOOD

GC/MS

CAFFEINE

LC/MS/MS

LC/MS/MS PERFORMED ON PERIPHERAL BLOOD
CAFFEINE, CAFFEINE METABOLITE
BLOOD IMMUNOASSAY SCREEN

SPECIMEN TYPE

PERIPHERAL BLOOD

AMPHETAMINES	NEGATIVE	mg/L	0.100
BARBITURATES	NEGATIVE	mg/L	0.100
BENZODIAZEPINES	NEGATIVE	mg/L	0.050
BUPRENORPHINE	NEGATIVE	mg/L	0.001
CANNABINOIDS	NEGATIVE	mg/L	0.050
COCAINE METABOLITE	NEGATIVE	mg/L	0.100
FENTANYL	NEGATIVE	mg/L	0.001
OPIATES	NEGATIVE	mg/L	0.050
SALICYLATES	NEGATIVE	mg/L	50.0

27/29/16


Patient: GRIMMIE, CHRISTINA
Client Patient ID: 9-16-903
Physician: STEPHANY, JOSHUA

Age: 22 **Sex:** F
Account#: VX82877
Client: DIST 9 MEDICAL EXAMINER



7/21/16

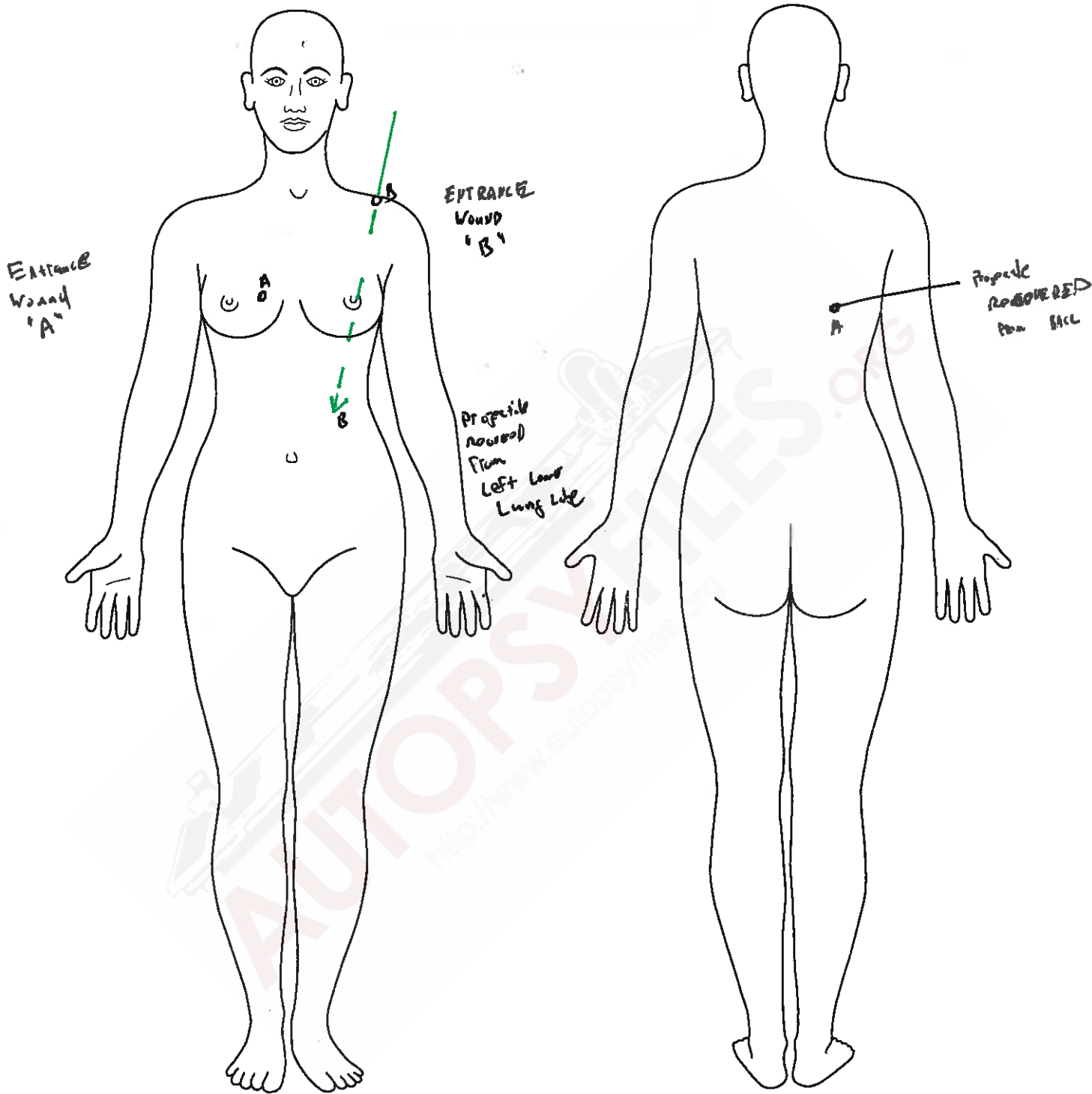
Specimens were intact upon receipt. Chain of custody, specimen security and integrity has been maintained. Testing has been performed as requested

Reviewed by:  Date: 7-15-16

FINAL REPORT - THIS COMPLETES REPORTING ON THIS CASE

TOXICOLOGY REPORT

GRIMMIE, CHRISTINA

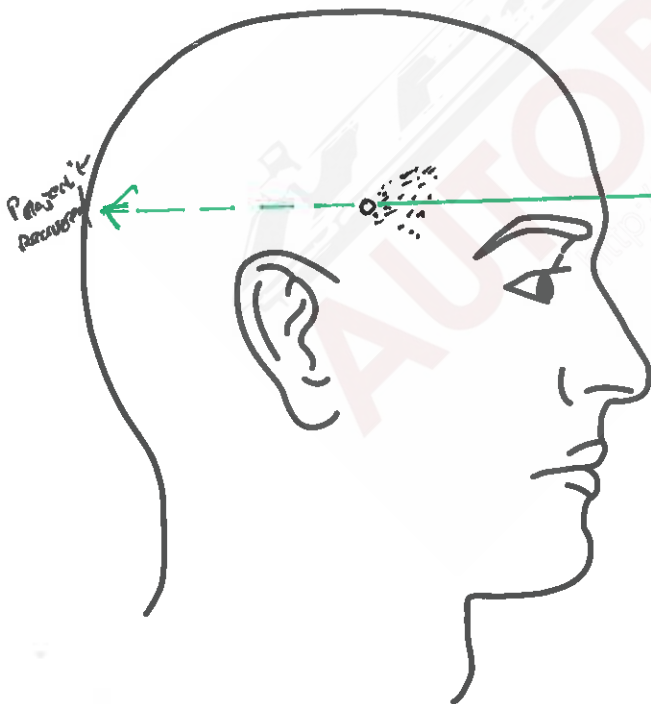
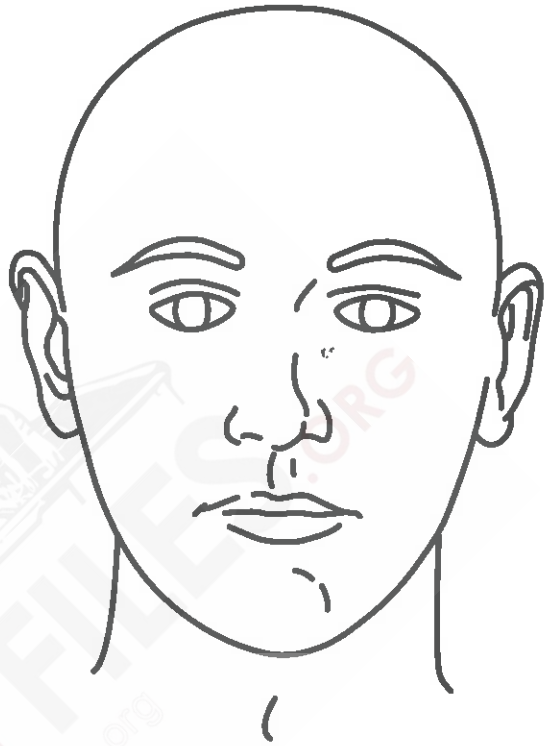
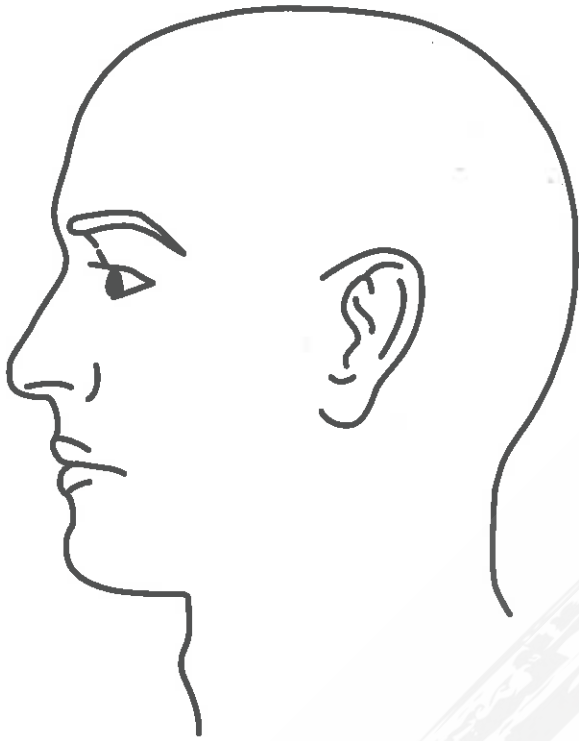


E16-00903

Grimmie, Christina ✓

22 Years - F

6/10/2016



Entrance wound
& Stippling

